

Expression of c-kit and kit-ligand in benign and malignant prostatic tissues

R. Simak¹, P. Capodiceci¹, D.W. Cohen¹, W.R. Fair¹, H. Scher³, J. Melamed²,
M. Drobnjak², W.D. Heston¹, U. Stix⁴, G. Steiner⁴ and C. Cordon-Cardo²

¹Urology Service, Department of Surgery, ²Department of Pathology, ³Division of Solid Tumor Oncology, Department of Medicine, Memorial Sloan-Kettering Cancer Center, New York, USA and ⁴Department of Urology, University of Vienna Medical School, Austria

Summary. The tyrosine kinase receptor c-kit and its ligand [kit ligand (KL) or stem cell factor (SCF)] exert a broad range of biological activities during organogenesis and normal cell development. Recent studies have revealed that altered c-kit levels occur in a variety of malignancies and cancer cell lines. KL has also been shown to stimulate the growth of malignant cells, as well as to promote chemotaxis. We had previously reported expression of KL in stroma cells of normal human prostate.

The present study was undertaken in order to analyze the patterns of expression of c-kit and KL in a well characterized set of prostatic tissues, including normal prostate (n=4), benign prostatic hyperplasia (BPH) (n=53) and adenocarcinoma (n=46) samples. The distribution of c-kit and KL proteins was studied by immunohistochemical analyses, while transcript levels were determined by in situ hybridization with specific RNA probes on a subset of the benign and malignant tissues referred above. In addition, reverse-transcriptase polymerase chain reaction (RT-PCR) was performed to determine levels of c-kit and KL expression in cultures of epithelial and stroma cells, as well as in the prostate cancer cell lines LNCaP, DU145 and PC3.

c-kit protein in normal prostate was exclusively detected in mast cells by immunohistochemistry and in situ hybridization. However, c-kit transcripts, but not c-kit protein, were detected in low levels and with an heterogeneous pattern in basal epithelial cells of ducts and acini. c-kit in BPH was detected in epithelial cells in 9 of 53 (17%) specimens. c-kit protein expression in malignant epithelial cells was identified in 1 of 46 (2%) tumors. However, c-kit transcripts were detected in low levels by in situ hybridization in most of the tumors analyzed.

KL protein and transcripts in normal prostate were detected in high levels in stroma cells. However, epithelial cells were unreactive for anti-KL antibody, but

showed low levels of KL transcripts mainly in cells of the basal layer. Basal epithelial cells in hyperplastic glands showed KL expression in 13 of 53 (24%) specimens. KL protein in tumor cells was noted in 18 of 46 (39%) cases.

c-kit transcripts were not found in normal prostate and in the 3 cancer cell lines analyzed by RT-PCR, however, it was present in cultured epithelial cells of BPH, and in cultures of stroma cells from both normal and BPH. The majority of cultured cell lines of epithelial and stromal origin displayed considerable levels of KL. In addition all prostate cell lines studied showed significant levels of KL transcripts.

In summary, co-expression of c-kit and KL in a subset of BPH cases may suggest an autocrine mode of signaling. Data from this study reveals that altered patterns of c-kit and KL expression are associated with BPH and adenocarcinoma of prostate. It appears that KL induces mast cells proliferation and maturation and enhances their release of protease. This could explain the accumulation of mast cells at tumor sites, a phenomenon that was not observed in normal prostate or BPH samples.

Key words: c-Kit, Kit ligand, Benign prostatic hyperplasia, Prostate neoplasms, Immunohistochemistry

Introduction

c-kit is a 145-160 kD transmembrane glycoprotein receptor of the tyrosine kinase family, which shares structural similarities with the receptors for the macrophage growth factor and for the platelet derived growth factor (Yarden et al., 1987). Mutations at the murine 'W' (white spotting) locus, homologous to the human c-kit, affect the development of hematopoietic stem cells, melanoblasts and primordial germ cells (Nocka et al., 1989), resulting in anemia, mast cell deficiency, depigmentation and sterility. A peptide growth factor has been identified as the ligand of c-kit, and alternately termed kit-ligand (KL), stem cell factor (SCF) or mast cell growth factor (MGF) (Huang et al.,

1990; Williams et al., 1990; Zsebo et al., 1990). KL is encoded at the murine 'Sl' (steel) locus, and exists both as a stable, membrane-bound molecule and as a soluble factor, released upon proteolytic cleavage from a cell-membrane bound form (Anderson et al., 1990; Flanagan et al., 1991; Huang et al., 1992). Alterations at the 'Sl' gene generate similar phenotypical deficiencies as those reported for 'W' mutations (Nakayama et al., 1988; Copeland et al., 1990; Huang et al., 1990; Zsebo et al., 1990).

The present study was undertaken following an immunohistochemical expression analysis conducted by our group of *c-kit* and KL in human normal tissues (Lammie et al., 1994). As part of that study, we observed a very restricted pattern of expression for KL, including high levels in prostatic fibromuscular stroma cells. *c-kit* was not detected in glandular epithelial cells or fibromuscular stroma cells of the prostate, but found to be expressed in tissue mast cells. Altered patterns of *c-kit* expression have been reported for germ cell tumors, lung cancer, breast cancer, melanomas and neuroblastoma (Strohmeyer et al., 1991; Natali et al., 1992; Beck et al., 1993; Matsuda et al., 1993). Moreover, KL has shown to stimulate growth of various *c-kit* expressing tumor cell lines, as well as mediating chemotaxis of small-cell lung cancer cells (Berdal et al., 1992; Sekido et al., 1993). Furthermore, it is well known that prostatic adenocarcinoma cells selectively metastasizes to bone (Jacobs, 1983), mainly to the axial skeleton (Willis, 1973). Considering the important role of KL at the sites of hematopoiesis, such as the bone marrow in adults, we hypothesized that KL may recreate a selective environment favoring prostate tumor cell seeding and growth within bone. We undertook the present study with the objective to further characterize the pattern of expression of *c-kit* and KL in normal prostate, benign prostatic hyperplasia (BPH) and prostatic adenocarcinoma using a panel of monoclonal antibodies and immunohistochemistry. Furthermore, in order to identify potential low levels of expression of these molecules, *in situ* hybridization and a reverse-transcriptase polymerase chain reaction (RT-PCR) methods were conducted on tissue sections and cell cultures of epithelial and stroma elements of normal prostate and BPH samples, respectively. These studies were also performed in a selected panel of prostate cancer cell lines, including LNCaP, DU145 and PC3.

Materials and methods

Patient characteristics and tissues

Samples of normal prostate, benign prostatic hyperplasia, and adenocarcinoma of the prostate were obtained from surgical specimens of 99 cases within 1-2 hours after surgery. Normal prostatic tissue from an additional 4 patients, age 20-24 years, was obtained from autopsy. Specimens were placed in OCT compound (Miles Laboratories, Elkhart, IN), snap frozen in

isopentane chilled in liquid nitrogen, and stored at -70 °C. Tissues were also fixed in buffered formalin and embedded in paraffin. Routine hematoxylin and eosin staining was performed on 5 micron sections from each specimen. After histopathological examination cases were classified as: normal prostate (n=4), benign prostatic hyperplasia (n=53) and prostatic adenocarcinoma (n=46).

Cell cultures

The human prostate cancer cell lines LNCaP, DU145 and PC3 were obtained from the American Type Culture Collection and cultured in RPMI-1640 medium (Gibco, Grand Island, NY), supplemented with 10% heat inactivated fetal calf serum, 100 U/ml penicillin and 100 mg/ml streptomycin. Cells were seeded at 3×10^5 cells and incubated at 37 °C in 7% CO₂ for 4 days, and then subcultured at 1:5 dilutions by trypsinization with 0.025% trypsin-1mM EDTA for 3 min at room temperature.

Additional tissues from benign prostatic hyperplasia (n=7) and normal prostate (n=5) were obtained immediately after transurethral prostatectomy and from accident victims (age < 25 years), respectively. Tissues were minced into 1-3 mm³ fragments and washed in PBS containing heparin (Novo Nordisk A/S, Bagsvaerd, Denmark) to minimize peripheral blood contamination. Tissue fragments were then incubated with 200 U/ml type-I collagenase (Sigma, St. Louis, MO) and 100 ug/ml DNase type I (Sigma) in RPMI 1640 plus 10% FCS and 6% penicillin/streptomycin solution (Gibco BRL, Gaithersburg, MD) and dissociated over night at 37 °C using a magnetic stirring bar, resulting in a heterogeneous cell suspension.

The enrichment of prostatic epithelial cells (EC) was performed as follows. Larger cell clusters were removed from cellular debris by short segmentation, washed in PBS and used for short term propagation of EC from normal prostate (EC-NP) or benign prostatic hyperplasia (EC-BPH). Cell clusters were cultured for 24 hours in 20 ml of RPMI plus 10% FCS in 175 cm³ culture flasks (Falcon, Becton-Dickinson, San Jose, CA). Adherent cells were harvested and enriched by sequential trypsin-EDTA (GIBCO) treatment. Only EC with distinctive adherence features were used for total RNA preparations. Cell suspensions of EC exhibited uniformly anti-cytokeratin-18 and anti-cytokeratin-5/15 immunoreactivities, confirming their epithelial origin. These cells were consistently negative for anti-CD45-antibody (Ab), a pan-leucocyte marker.

The enrichment of prostatic stroma cells (SC) was performed using samples derived from the same tissues utilized for EC cultures. Briefly, normal prostatic and BPH tissue-derived heterogeneous cell suspensions were centrifugated and filtered through nylon wool, followed by density centrifugation over a 20% Percoll gradient (Pharmacia, Uppsalla, Sweden) for 10 min at 1200 rpm. Nonviable cells were removed by Lymphoprep™

gradient centrifugation over 20 min at 1600 rpm, and the remaining viable cells were then used for stroma cultures. Polyclonal prostatic SC lines were grown in the same medium as described above. Contamination with leucocytes and/or EC was excluded by propagation of SC over several passages before use. All SC lines exhibited a characteristic morphology and showed no immunoreactivity against anti-cytokeratin 5/15 and anti-CD45 antibodies. In contrast, SC were strongly immunoreactive against anti-vimentin and anti-desmin antibodies.

Antibodies and immunohistochemistry

SR-1 is a mouse monoclonal antibody (MoAb) of the IgG2a subclass which recognizes an epitope located in the extracellular domain (ligand-binding region) of the human c-kit receptor (Lammie et al., 1994). 7H6 is a mouse MoAb which recognizes a specific determinant carried by the kit-ligand (KL) (Lammie et al., 1994). These two antibodies were kindly supplied by Amgen Inc, Thousand Oaks, CA. Mouse monoclonal antibody 348E12 (Enzo Laboratories, New York, NY) was raised against stratum corneum and is immunoreactive with cytokeratins M_r 49,000, 51,000, 57,000 and 66,000 (Gown and Vogel, 1984). Mouse monoclonal antibody HHF35 (Dako Corporation, Carpinteria, CA) detects muscle actin (also known as "muscle common actin"), while mouse MoAb 1A4 (Dako Corporation) reacts with the alpha-smooth muscle isoform of actin (Skalli et al., 1986; Tsukada et al., 1987).

Primary antibodies were diluted in phosphate buffered saline (PBS) containing 2% bovine serum albumin (BSA) to a concentration giving maximal intensity without non-specific staining. After titration assays, the final working dilutions were 1:100 for SR-1, 1:2,000 for 7H6 and 348E12, 1:8,000 for HHF35, and 1:30,000 for 1A4. The secondary antibodies were biotinylated horse anti-mouse IgG (Vector Laboratories, Burlingame, CA) and were utilized at a 1:500 dilution in PBS.

All reactions, with the exception of fixation, were carried out at room temperature, using the avidin-biotin immunoperoxidase technique (Lammie et al., 1994). Consecutive frozen sections were air dried, fixed in acetone for 10 min at 4 °C and washed in PBS. Endogenous peroxidase activity was blocked by immersion in 0.1% hydrogen peroxide for 10 min. After washing in PBS, sections were subsequently incubated for 15 min with solutions 'Avidin D' and 'Biotin' (Vector Laboratories) in order to block endogenous biotin activity. Normal horse serum (Organon Tecknika Corporation, Westchester, PA) (10% final dilution in 2% BSA/PBS) was applied as a blocking agent to minimize background staining. Primary antibodies were applied for 1 hour, biotinylated secondary antibodies for 30 minutes and avidin-biotin-peroxidase complexes (Vector) (1:25 in PBS) for 30 minutes. Each incubation was followed by washing in PBS. Sections were

developed with 0.05% diamino-benzidine tetrachloride (Sigma) and 0.01 hydrogen peroxide in PBS/0.5% Triton, counterstained with hematoxylin, dehydrated, and mounted with Permount.

Controls included the use of S1/S14 human SCF 220 cells (91-15-234-1) and S1/S4 cells (91-15-233-1) (both supplied by Amgen Inc), which served as positive and negative controls for 7H6 staining (Lammie et al., 1994). For SR-1 staining, the GEM OCIM-1 cell line (Amgen Inc) was used as the positive control (Lammie et al., 1994). Normal human tissues, including skin and skeletal muscle, known to express cytokeratins and actin-isoforms, were used for the other antibodies. Negative control reagents included isotype class-matched, non-specific IgG antibodies (Coulter Immunology, Hialeah, FL) and substitution of the primary antibody by normal serum.

Probes and in situ hybridization

1 µg of recombinant plasmid pBluescript KS+ containing the full length mouse c-kit receptor and 1 µg of plasmid pcDNA 1 containing full length mouse kit-ligand-1 were linearized by Hind III/EcoRI and XbaI/HindIII, respectively, to generate antisense and sense digoxigenin-labeled riboprobes (DeLellis, 1994). Riboprobes were generated with T3, T7 and SP6 polymerase for 2 hours at 37 °C in 1X transcription buffer (Boehringer Mannheim, Indianapolis, IN), 20U of RNase inhibitor, 1 mmol/L each of ATP, GTP, CTP, 6.5 mmol/L UTP and 3.5 mmol/L digoxigenin-UTP. Proteinase K was prepared at a final concentration of 50 µg/ml in Tris/EDTA buffer. The slides were treated for 18 minutes at 37 °C and post-fixed at 4 °C in a freshly prepared solution of 4% paraformaldehyde in PBS for 5 minutes. They were acetylated in a solution 0.25% acetic anhydride/0.1M triethanolamine for 10 minutes. Prehybridization for 30 minutes at 42 °C in 50% formamide and 2X SSC. The hybridization buffer consisted of 50% deionized formamide (v/v), 10% dextran sulphate (50% stock solution), 2X SSC (20X stock solution), 1% SDS (10% stock solution), 0.25 mg/ml of herring sperm DNA (10 mg/ml). Hybridization was performed overnight at 42 °C applying 10 pmol/L digoxigenin-labeled riboprobe in 50 ml of hybridization buffer per section under a coverslip. Stringency washes in 2X SSC, 0.5X SSC and 0.01X SSC at 60 °C for 20 minutes, respectively (DeLellis, 1994). The slides were incubated with antibody anti-digoxigenin-AP (Boehringer Mannheim, Indianapolis, IN) at a dilution of 1:500 for 1 hour. The visualization was accomplished by nitro-blue-tetrazolium/5-bromo-4-chloro-3-indoyl-phosphate. The slides were counterstained with methyl green and mounted in Permount (DeLellis, 1994).

RT-PCR assays

RNA preparation was performed as described previously (Chromczynski and Sacchi, 1987). Single-

Table 1. Expression of KL and c-KIT in benign and malignant prostatic tissue.

	NORMAL PROSTATE (n=4)			BENIGN PROSTATIC HYPERPLASIA (n=53)			PROSTATIC CARCINOMA (n=46)	
	Fibromuscular stroma cells	Epithelial cells		Fibromuscular stroma cells	Epithelial cells		Fibromuscular stroma cells	Tumor cells
		Basal	Luminal		Basal	Luminal		
KL	+ ¹	-	-	+	+ & - (13/53) ²	-	+	+ & - (18/46)
c-KIT	-. ³	-	-	-	+ & - (9/53)	-	-. ⁴	+ & - (1/46)

¹+ : intense and homogeneous immunostaining; + & -: intense and heterogeneous immunostaining; -: undetectable immunoreactivity; ²: number of positive cases/total number of cases studied; ³: mast cells of stroma positive for c-kit; ⁴: Increased number of mast cells

stranded cDNA was obtained by reverse transcription of 1 µg of total RNA following the guidelines of the manufacturer (GeneAmp RNA PCR kit, Perkin Elmer/Roche, Branchburg, NJ). Reaction mixtures were incubated at 42 °C for 1 hour and excess of enzyme was inactivated at 95 °C for 5 min. Amounts of cDNA were adjusted using 20 cycles with specific primers for beta 2-microglobulin (5'-ACCCCACTGAAAAAGATGA-3' and 5'-CAACCATGCCTTACTTTATC-3'). The oligonucleotides used as primers were: 5'-ATGAGAGGCGC TCGCGGCGC-3' and 5'-AGCTTGGCAGGATCTCTA AC-3' for c-kit (Yarden et al., 1987); 5'-GATGGTAG TACAATTGTCAGAC-3' and 5'-CTTAATGTTGAAGA AAC-3' for KL (Martin et al., 1990). Reaction mixtures were first heated to 94 °C for 5 min, and then 35 cycles of 94 °C for 1 min, 42 °C for 2 min and 72 °C for 1 min were carried out in a DNA thermal cycler (Perkin Elmer, Norwalk, CT). The products were separated on a 1.5% agarose gel and visualized by ethidium bromide staining. All RT-PCR assays were conducted as three independent runs in order to confirm the results obtained.

Blotting of PCR products with specific probes (see below) was then conducted. Briefly, cDNA was transferred to positively charged nylon membranes by capillary blotting. Prehybridization and hybridization of the membranes with ExpressHyb solution was done following the instructions of the manufacturer (Clontech, Palo Alto, CA), using labeled internal oligonucleotides specific for c-kit (5'-AGAAGCCAC CAACACCGGCA-3') (Yarden et al., 1987) and for KL (5'-GTAGTGG CATCTGAACTAGTG-3') (Brawer et al., 1985). Probes were labeled using digoxigenin (DIG) tailing with DIG-dUTP (Boehringer Mannheim, Germany). DIG nucleic acid detection (DIG Nucleic Acid Detection Kit; Boehringer Mannheim, Germany) was applied after incubation with anti-DIG antibody conjugated with alkaline phosphatase.

Results

Table 1 summarizes the results of the immunohistochemical stainings with c-kit and KL antibodies in specimens from 103 cases with regard to the immunoreactivity observed in either normal, benign hyperplastic

or malignant prostatic tissues. Figs. 1 and 2 illustrate the microanatomical patterns of expression of c-kit and KL at the protein level by immunohistochemistry and mRNA levels by *in situ* hybridization, respectively. Fig. 3 illustrates expression of c-kit and kit-ligand transcripts by RT-PCR.

Immunohistochemical and in situ hybridization analyses of c-kit and KL in normal prostate

Cytoplasmic immunoreactivity to c-kit was seen in scattered, mononuclear stroma cells with granular cytoplasm. In a preliminary study from our laboratory, toluidin blue-induced metachromasia was used to identify these cells as mast cells (Lammie et al., 1994). Epithelial cells of glands and ducts, lymphocytes, vascular endothelial cells and nerves were unreactive to c-kit antibody. Only low levels of the transcript were detected by *in situ* hybridization in basal epithelial cells of prostatic ducts and acini.

A different pattern of expression was observed for KL, which was identified as an intense cytoplasmic immunoreactivity in fibromuscular stroma cells (Fig. 1A), confirming previously reported results (Lammie et al., 1994). Smooth muscle cells in the vessel walls of small arteries and arterioles stained positive, but those in the tunica media of larger arteries were unreactive. Glandular and ductal epithelial cells showed no KL expression. *In situ* hybridization for KL showed the message in the fibromuscular stroma elements, as well as in the basal epithelial cells of ducts and acini.

Immunohistochemical and in situ hybridization analyses of c-kit and KL in benign prostatic hyperplasia

c-kit immunoreactivity within the stroma of BPH specimens was still restricted to mast cells. However, c-kit expression in epithelial cells of hyperplastic glands was observed in 9 of 53 specimens. The staining pattern was focal mainly within acini of hyperplastic nodules. Very low levels of c-kit transcript were detected in basal epithelial cells of glands and ducts (Fig. 2A).

Similar changes were noted for KL-expression in BPH specimens. Immunoreactivity was intense for fibromuscular stroma cells, and even more pronounced

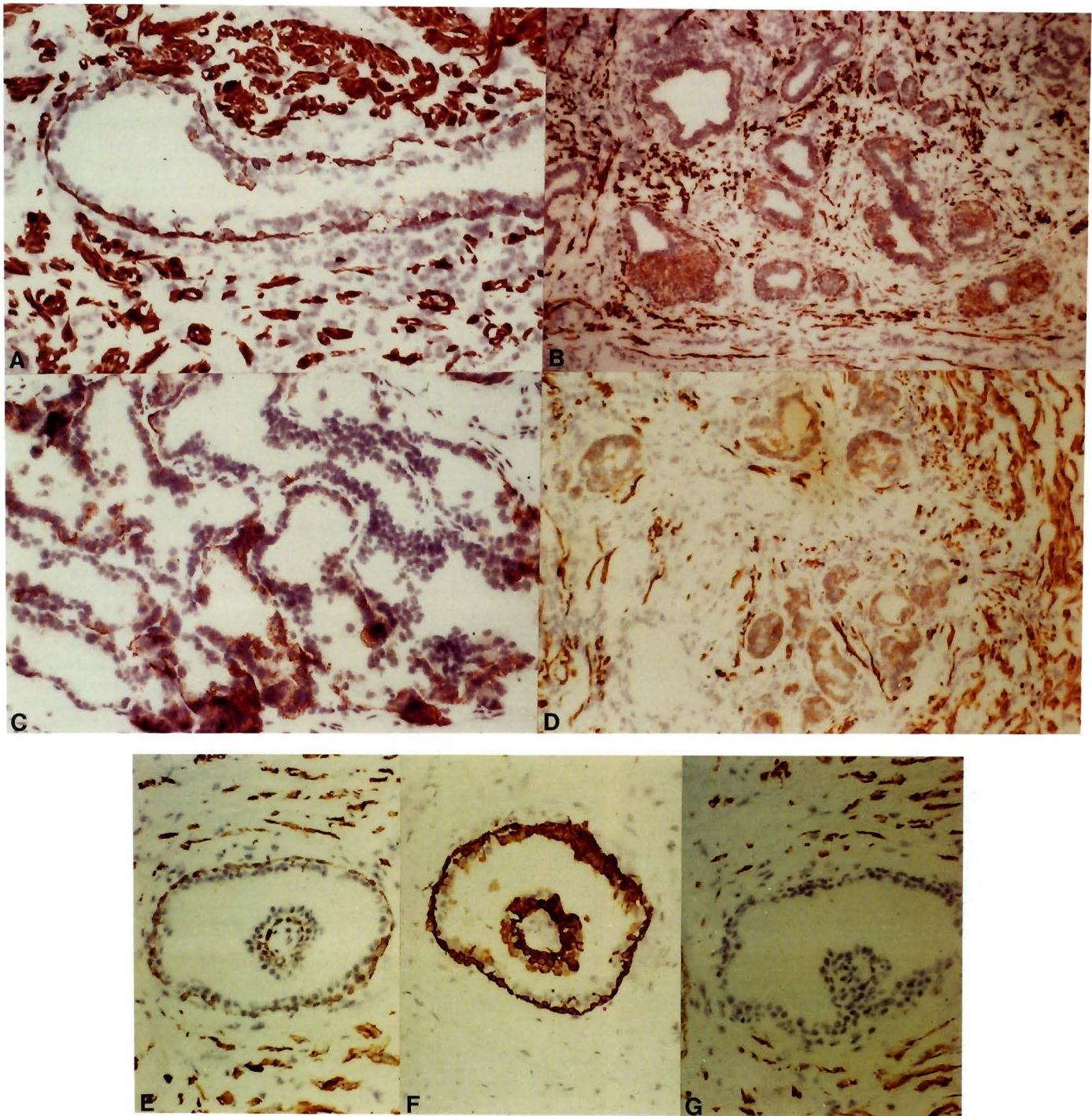


Fig. 1. Patterns of KL and c-kit expression in benign and malignant prostatic tissues by immunohistochemical assays. **A.** Basal epithelial cells of a duct in a normal prostate sample expressing KL. Luminal epithelial cells remain unreactive to anti-KL antibody. Note the intense immunostaining of fibromuscular stroma cells. **B.** Basal cell hyperplasia showing KL being expressed by basal and suprabasal epithelial cells. **C.** Prostatic adenocarcinoma showing heterogeneous expression of c-kit in epithelial tumor cells (see arrow heads). Cytoplasmic and membrane staining patterns were identified. **D.** Prostatic adenocarcinoma revealing epithelial tumor cells with cytoplasmatic expression of KL. Note the strong KL staining of fibromuscular stroma cells. **E, F, G)** Co-expression of KL (**E**) and cytokeratins (**F**) in basal epithelial cells of a BPH specimen. However, these basal epithelial cells immunoreactive with anti-KL antibody lack expression of muscle common actin (**G**). Note the intense staining of fibromuscular stroma cells (**G**). A, x 200; B, x 100; C, x 200; D, x 100; E,F,G, x 200

within hyperplastic nodules. In 13 of 53 specimens, KL-immunostaining of epithelial cells was strikingly different from that seen in normal prostate. We noted in those specimens that basal cells of both ducts and acini heterogeneously displayed an intense cytoplasmic staining. Comparing consecutive sections stained with both c-kit and KL antibodies revealed that co-expression of these molecules in epithelial cells occurred in 5 BPH specimens. In acini with morphological features of basal cell hyperplasia, KL-expression was no longer confined to the basal layer, and could be seen in suprabasal cells (Fig. 1B). Moderate mRNA levels were found by in situ

hybridization in the fibromuscular cells of BPH samples. In addition, low KL transcript levels were also identified in the basal epithelial cell layer of acini (Fig. 2C).

Immunohistochemical and in situ hybridization. Analyses of c-kit and KL in prostatic adeno-carcinoma

c-kit immunoreactivity in epithelial tumor cells was seen only in one specimen (Fig. 1C). In this specific case, groups of malignant cells showed strong cytoplasmic and membrane immunoreactivity. c-kit immunostaining revealed an increased mast cell content

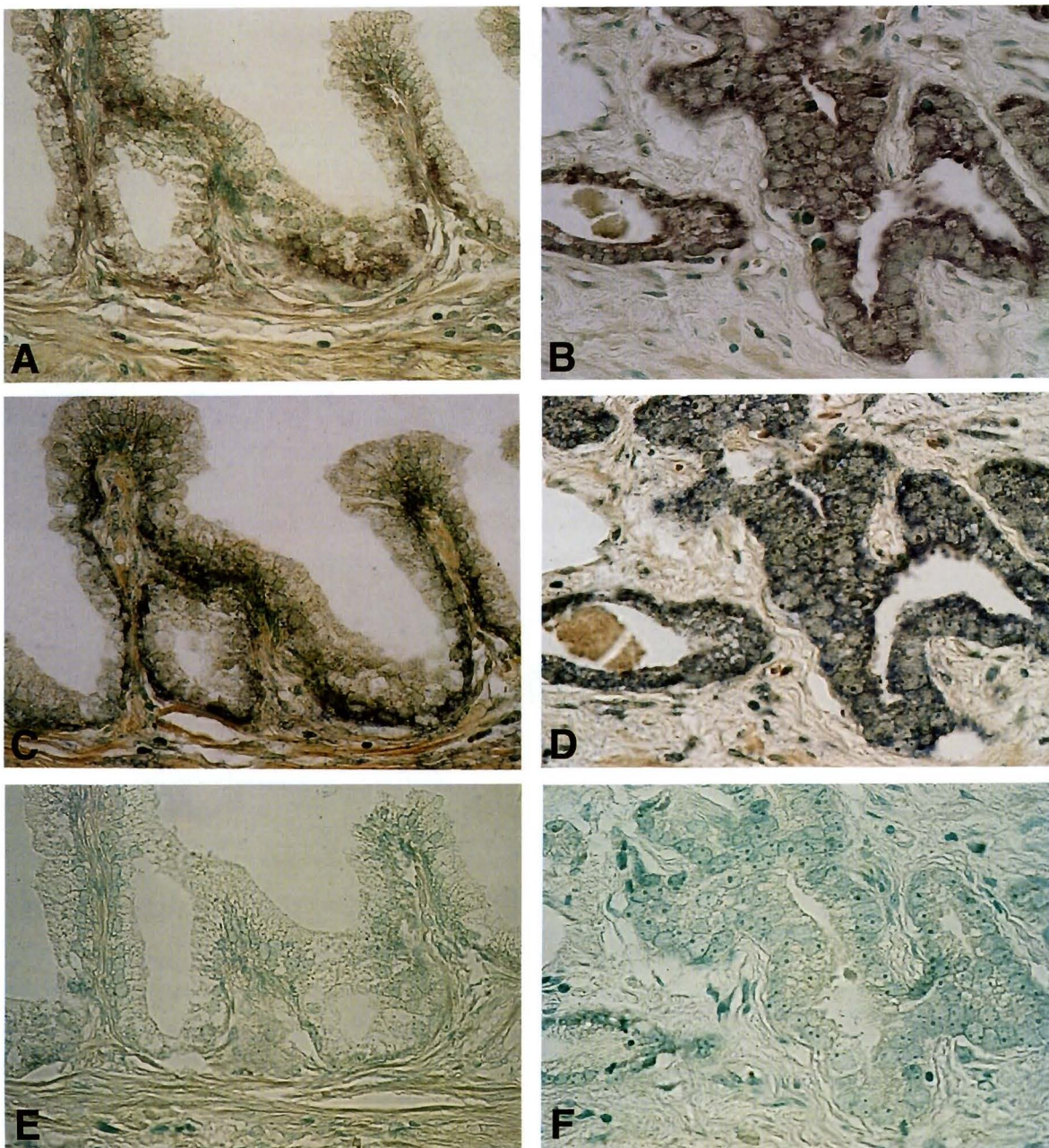


Fig. 2. Patterns of KL and c-kit expression in benign and malignant prostatic tissues by in situ hybridization using antisense and sense probes. **A and C.** Basal epithelial cells of a gland in a benign prostatic hyperplasia sample expressing c-kit and kit-ligand respectively. Note the low level of message. **E.** Consecutive section of the same tissue sample using the sense probe as a negative control. **B and D.** Area of prostatic adenocarcinoma showing the low level of c-kit and moderate level of kit-ligand mRNA. **F.** Consecutive section of the same tissue sample using the sense probe as a negative control. x 400

in peritumoral and endotumoral areas, regardless of local inflammatory infiltrates. In contrast to c-kit, tumor cells with cyto-plasmic KL expression were a frequent finding, and were noted in 18 of 46 specimen (Fig. 1D), including the carcinoma case identified with c-kit-immunoreactive tumor cells. Similar to the pattern of epithelial KL staining in BPH, immunoreactivity was heterogenous but very pronounced within each positive specimen. c-kit and KL transcripts were present, but in low levels, on tumor cells in all samples analyzed, as shown in Fig. 2B,D, respectively.

Phenotypic characterization of KL and c-kit expressing cells

In order to better define the phenotype of KL and c-kit positive cells, we stained consecutive sections of selected BPH and prostatic adenocarcinoma cases with antibodies to cytokeratins and actin isoforms. We observed co-expression of KL and cytokeratins in basal epithelial cells in a subset of benign hyperplastic tissues (Fig. 1E,F). Luminal cells remained unreactive for 34 β E12 anti-cytokeratin antibody. We also found that cases displaying basal cell hyperplasia had strong cytokeratin staining of basal and suprabasal cells. Nevertheless, malignant epithelial cells failed to react with antibody 34 β E12. Staining with anti-muscle actin (MA) and anti-smooth muscle actin (SMA) antibodies showed that fibromuscular but not basal cells co-expressed KL and actin isoforms (Fig. 1G). It should be

noted that smooth muscle cells of small vessels and arterioles also co-expressed SMA and KL proteins. Nevertheless, we observed that the smooth muscle cells of the tunica media of larger arteries, although KL-negative, still reacted with anti-actin antibodies.

RT-PCR analyses of c-kit and KL in cell cultures from normal prostate and BPH samples, as well as prostate cancer cell lines

In order to detect potential low levels of expression of c-kit and KL in specific cell types, we extended our study to the analysis of mRNA transcripts in cultured epithelial and stroma cells. The choice of studying cultured cells was based on the premise of avoiding contamination of distinctive cell populations present in the normal and BPH samples, such as mast cells. We observed that levels of c-kit transcripts were detectable in cultured epithelial cells of BPH, but not of normal prostate or any of the three prostate cancer cell lines studied (Fig. 3). However, c-kit transcripts were identified in representative cultures of stroma cells from both normal and BPH cases (Fig. 3).

A different pattern of transcript levels was found for KL, since the majority of cultured cells, both of epithelial and stroma origin, displayed considerable levels of KL (Fig. 3). Nevertheless, only one of 5 samples of epithelial cell cultures from normal prostate showed detectable KL transcripts. All prostate cancer cell lines studied revealed significant levels of KL

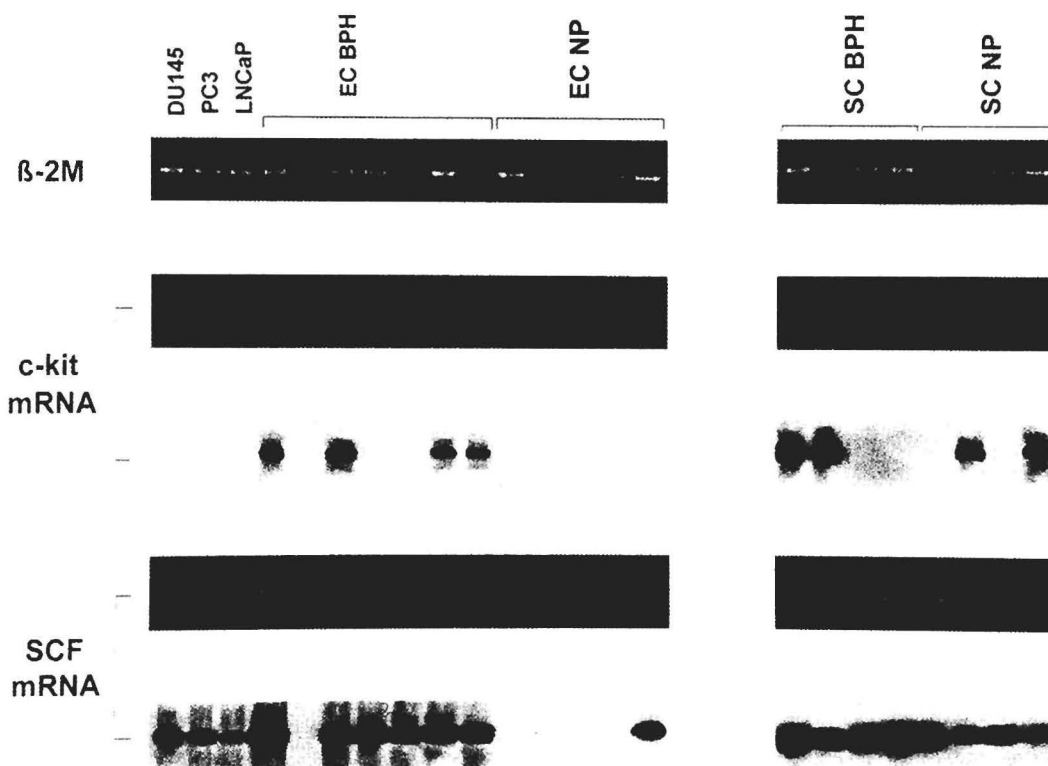


Fig. 3. Levels of KL and c-kit transcripts in cultured epithelial and stroma cells from normal prostate and benign prostatic hyperplasia samples, as well as in prostate cancer cell lines. The beta-2-microglobulin served as an internal control to all RT-PCR reactions. Bands with similar intensity were identified in all lanes of the samples studied. c-kit transcripts were not detected in any of the three prostate cancer cell lines, nor in the epithelial cell cultures from normal prostate. However, four of the 7 epithelial cell cultures from BPH samples expressed c-kit transcripts. Several stroma cell cultures from both normal and BPH samples revealed c-kit expression. KL/SCF transcripts were identified in the majority of samples studied, including all prostate cancer cell lines.

transcripts (Fig. 3).

Discussion

The major finding in this study was the presence of the tyrosine protein kinase receptor *c-kit* and its ligand in subsets of prostate cells. As mentioned, we previously showed that detectable KL expression in normal tissues is limited to few organs, including the prostate, and that the staining of the prostatic fibromuscular stroma with anti-KL antibody was particularly intense (Lammie et al., 1994). We found KL and *c-kit* being expressed in distinct cells within the normal prostate, although in cells confined to the stroma compartment. The present study demonstrates that benign prostatic hyperplasia and prostatic adenocarcinoma are associated with alterations of this basic pattern of expression. In addition to stroma elements, a considerable number of these cases showed detectable levels of KL in epithelial cells within hyperplastic glands and malignant tissues. Detectable *c-kit* levels were also seen in malignant epithelial cells, even though that phenotype was only identified in one adenocarcinoma specimen by immunohistochemistry, and was lacking in the prostate cancer cell lines studied by RT-PCR. This observation contrasts the findings in prostatic hyperplasia, where *c-kit* was expressed on epithelial cells in 9 of 53 cases by immunohistochemistry, as well as in 4 of 7 epithelial cell cultures from BPH samples by RT-PCR. However, *in situ* hybridization revealed that low to moderate *c-kit* mRNA levels were present in both BPH and tumor samples analyzed.

The pattern of *c-kit*/KL expression in human prostate tissues suggests different pathways of signal transduction. KL released from fibromuscular stroma cells may interact in a paracrine pathway with connective tissue mast cells and a subpopulation of epithelial cells in BPH cases. The sparse nature of mast cells in normal prostatic tissue and BPH in contrast to the considerable amount of KL points to this alternative use of the ligand by epithelial and/or fibromuscular cells themselves. The lack of staining for *c-kit* and the undetectable *c-kit* transcripts in epithelial cells from the normal prostate confirms the genuine negative *c-kit* phenotype of these cells, and reveals an important difference between epithelial cells of the normal gland and those from hyperplastic prostate. Moreover, the observation that a subset of BPH cases co-expressed KL and *c-kit* in their epithelial cells suggests a shift towards an autocrine mode of signaling. Such autocrine loops have been proposed to function by allowing cells to escape growth control from their environment (Aaronsen, 1991).

The undetectable levels of *c-kit* in neoplastic epithelial cells could be explained by low levels of the receptor being expressed. However, RT-PCR data on prostate cancer cell lines in this study confirm this observation. Alternatively, detectable *c-kit* in some primary tumors may be masked by a high degree of occupancy by the ligand (Langley et al., 1993) or

masking of the epitope recognized by the antibody used in the study. Another critical issue is the potential down-regulation of receptors in transformed cells. For *c-kit* this phenomenon has been reported in breast and small cell lung carcinomas, as well as in melanoma cells (Natali et al., 1992a,b).

Another frequent finding was the abundance of mast cells seen in the peritumoral stroma and in close proximity to tumor cells. Although mast cells were reported at the edge of human tumors as early as 1879 (Ehrlich, 1879), much controversy still exists about the functional significance of their accumulation at tumor sites. Several studies proposed that they had a protective role against tumors, based on the release of cytotoxic agents during degranulation (Farram and Nelson, 1980; Burtin et al., 1985). In contrast, other studies have suggested a supportive role of mast cells in tumor growth. The heparin released from mast cell was proposed to stimulate the migration of capillary endothelial cells *in vitro* (Azizkhan et al., 1980). In addition, heparin has been shown to be mitogenic for endothelial cells (Marks et al., 1986). These effects may potentiate angiogenesis, an indispensable step in tumor growth (Folkman et al., 1963). Mast cells also release proteases that may be involved in tumor invasion and connective tissue degradation (Dabbous et al., 1986; Gruber and Schwartz, 1988, 1990). Among various mast cell recruitment factors, KL ranges as one of the most potent chemoattractants (Meininger et al., 1992). It induces mast cell proliferation and maturation, and enhances their release of proteases (Tsai et al., 1991). Most important, KL-induced expansion of mast cell populations has shown to be dose-dependant (Galli et al., 1993). This observation could explain why mast cells in our series were accumulated in the proximity of tumors, but not in BPH or normal prostate tissues. In these samples, KL would be confined to the microenvironment since a basement membrane isolates epithelial cells from the surrounding stroma compartment. KL was consistently expressed by fibromuscular stroma cells, but was also detected more frequently on epithelial cells of malignant cases than benign hyperplastic samples. It is then conceivable that even subtle changes in KL tissue levels in invasive neoplasms may regulate mast cell recruitment and their function at tumor sites.

Another critical aim of our study was to further determine the phenotype of cells that express *c-kit* or KL in benign and malignant prostate tissues. Smooth muscle cells in bladder and myometrium express KL (Lammie et al., 1994), and the staining intensity of some basal epithelial cells for KL in some BPH specimens was similar to that seen in prostatic cells of the fibromuscular stroma. Epithelial cells lining the basement membrane in the prostate have been termed 'myoepithelial' cells due to their morphological resemblance to myoepithelial cells found in other organs. True 'myoepithelial' cells, such as those found in breast ducts and acini, were shown to contain intermediate-size filaments belonging to the cytokeratin family and contractile proteins, including

actin, myosin and alpha actinin (Francke et al., 1980; Lazard et al., 1993). In contrast, KL immunoreactive basal epithelial cells in BPH were positive for anti-cytokeratin antibody 34 β E12, but not for anti-actin isoforms antibodies, indicating that these cells are not myoepithelial but epithelial in nature. Moreover, 34 β E12 antibody allows the selective staining of differentiated basal epithelial cells and basal cell hyperplasia, while it is unreactive with intraductal neoplasia and adenocarcinoma (Brawer et al., 1985; Hendrick and Epstein, 1989).

In conclusion, altered patterns of c-kit and KL expression are frequent and are associated with benign hyperplasia and adenocarcinoma of prostate. Whether KL or c-kit selectively favor malignant prostatic cell growth or spread to distant sites, namely bone, needs to be further characterized. In addition, tumor associated changes in the mast cell content are in keeping with previously reported studies and stress the need for additional information regarding the effects of KL on mast cells at tumor sites.

Acknowledgements. This work was in part supported by Grant J0719-MED from the 'Fonds fuer Wissenschaft und Forschung', NIH Grant DK47650 and the PepsiCo Foundation.

References

- Aaronson S.A. (1991). Growth factors and cancer. *Science* 254, 1146-1153.
- Anderson D.M., Lyman S.D., Baird A., Wignall J.M., Eisenman J., Rauch C., March C.J., Boswell H.S., Gimpel S.D., Cosman D. and Williams D.E. (1990). Molecular cloning of mast cell growth factor, a hematopoietin that is active in both membrane bound and soluble forms. *Cell* 63, 235-243.
- Azizkhan R.G., Azizkhan J.C., Zetter B.R. and Folkman J. (1980). Mast cell heparin stimulates migration of capillary endothelial cells in vitro. *J. Exp. Med.* 152, 931-944.
- Beck D., Gross N. and Beretta C. (1993). Expression and functional role of the proto-oncogene c-kit in human neuroblastoma (NBL) cells. *Proc. Annu. Meet. Am. Assoc. Cancer. Res.* 34A, 307.
- Berdel W.E., de Vos S., Maurer J., Oberberg D., von Marschall Z., Schroeder J.K., Li J., Ludwig W.D., Kreuser E.D., Thiel E. and Hermann F. (1992). Recombinant human stem cell factor stimulates growth of a human glioblastoma cell line expressing c-kit proto-oncogene. *Cancer Res.* 52, 3498-3502.
- Brawer M.K., Peehl D.M., Stamey T.A. and Bostwick D.G. (1985). Keratin immunoreactivity in the benign and neoplastic human prostate. *Cancer Res.* 45, 3663-3667.
- Burtin C., Ponvert C., Fray A., Scheinmann P., Lespinats G., Loidon B., Canu P. and Paupe J. (1985). Inverse correlation between tumor incidence and tissue histamine levels in w/w^v, wv/v and +/- mice. *J. Natl. Cancer Inst.* 74, 671-674.
- Chromczynski P. and Sacchi N. (1987). Single step method of RNA isolation by acid guanidinium thiocyanate-phenol-chloroform extraction. *Anal. Biochem.* 162, 156-159.
- Copeland N.G., Gilbert D.J., Cho B.C., Donovan P.J., Jenkins N.A., Cosman D., Anderson D., Lyman S.D. and Williams D.E. (1990). Mast cell growth factor maps near the steel locus on mouse chromosome 10 and is deleted in a number of steel alleles. *Cell* 63, 175-183.
- Dabbous M.K., Walker R., Haney L., Carter L.M., Nicolson G.L. and Woolley D.E. (1986). Mast cells and matrix degradation at sites of tumour invasion in rat mammary adenocarcinoma. *Br. J. Cancer* 54, 459-465.
- DeLellis R.A. (1994). In situ hybridization techniques for the analysis of gene expression: applications in tumor pathology. *Hum. Pathol.* 25, 580-585.
- Ehrlich P. (1879). Beitrage zur Kenntniss der granulierten Bindegewebszellen und der eosinophilen Leukocyten. *Arch. Anat. Physiol.* 166-171.
- Farram E. and Nelson D.S. (1980). Mouse mast cells as anti-tumor effector cells. *Cell Immunol.* 55, 294-298.
- Flanagan J.G., Chan D.C. and Leder P. (1991). Transmembrane form of the kit ligand growth factor is determined by alternative splicing and is missing in the Sl^d mutant. *Cell* 64, 1025-1035.
- Folkman J., Long D.M. and Becker F.F. (1963). Growth and metastasis of tumor in organ culture. *Cancer* 16, 453-467.
- Francke W.W., Schmid E. and Freudenstein C. (1980). Intermediate-sized filaments of the prekeratin type in myoepithelial cells. *J. Cell Biol.* 84, 633-654.
- Galli S.J., Iemura A., Garlick D.S., Gamba-Vitalo C., Zsebo K.M. and Andrews R.G. (1993). Reversible expansion of primate mast cell populations in vivo by stem cell factor. *J. Clin. Invest.* 91, 148-152.
- Gown A.M. and Vogel A.M. (1984). Monoclonal antibodies to human intermediate filament proteins. II. Distribution of filament proteins in normal human tissues. *Am. J. Pathol.* 114, 309-321.
- Gruber B.L., Schwartz L.B., Ramamurthy N.S., Irani A.M. and Marchese M.J. (1988). Activation of latent rheumatoid synovial collagenase by human mast cell tryptase. *J. Immunol.* 140, 3936-3942.
- Gruber B.L. and Schwartz L.B. (1990). The mast cell as an effector of connective tissue degradation: a study of matrix susceptibility to human mast cells. *Biochem. Biophys. Res. Commun.* 171, 1272-1278.
- Hendrick L. and Epstein J. (1989). Use of keratin 903 as an adjunct in the diagnosis of prostate carcinoma. *Am. J. Pathol.* 13, 389-396.
- Huang E., Nocka K., Beier D.R., Chu T.Y., Buck J., Lahm H.W., Wellner D., Leder P. and Besmer P. (1990). The hematopoietic growth factor KL is encoded by the Sl locus as is the ligand of the c-kit receptor, the gene product of the W locus. *Cell* 63, 225-233.
- Huang E.J., Nocka K.H., Buck J. and Besmer P. (1992). Differential expression and processing of two cell associated forms of the kit-ligand: KL-1 and KL-2. *Mol. Biol. Cell* 3, 349-362.
- Jacobs S.J. (1983). Spread of prostatic cancer to bone. *Urology* 21, 337-344.
- Lammie A., Drobnjak M., Gerald W., Saad A., Cote R. and Cordon-Cardo C. (1994). Expression of c-Kit and Kit ligand proteins in human normal tissues. *J. Histochem. Cytochem.* 42, 1417-1425.
- Langley K.E., Bennett L.G., Wypych J., Yancik S.A., Liu X.D., Westcott K.R., Chang D.G., Smith K.A. and Zsebo K.M. (1993). Soluble stem cell factor in human serum. *Blood* 81, 656-660.
- Lazard D., Sastre X., Frid M.G., Glukhova M.A., Thiery J.P. and Koteliansky V.E. (1993). Expression of smooth muscle-specific proteins in myoepithelium and stroma myofibroblasts of normal and malignant human breast tissue. *Proc. Natl. Acad. Sci. USA* 90, 999-1003.
- Marks R.M., Roche W.R., Czerniecki M., Czerniecki M., Penny R. and

- Nelson D.S. (1986). Mast cell granules cause proliferation of human microvascular endothelial cells. *Lab. Invest.* 55, 289-294.
- Martin F.H., Suggs S.V., Langley K.E., Lu H.S., Ting J., Okino K.H., Morris C.F., McNiece I.K., Jacobsen F.W., Mendiaz E.A., Birkett N.C., Smith K.A., Johnson M.J., Parker V.P., Flores J.C., Patel A.C., Fisher E.F., Erjavec H.O., Herrera C.J., Wypych J., Sachdev R.K., Pope J.A., Leslie I., Wen D., Lin C-H., Cupples R.L. and Zsebo K.M. (1990). Primary structure and functional expression of rat and human stem cell factor DNAs. *Cell* 63, 203-211.
- Matsuda R., Takahashi T., Nakamura S., Sekido Y., Nishida K., Seto M., Seito T., Sugiura T., Ariyoshi Y., Takahashi T. and Ueda R. (1993). Expression of the c-kit protein in human solid tumors and in corresponding fetal and adult normal tissues. *Am. J. Pathol.* 142, 339-346.
- Meininger C.J., Yano H., Rottapel R., Bernstein A., Zsebo K.M. and Zetter B.R. (1992). The c-kit receptor ligand functions as a mast cell chemoattractant. *Blood* 79, 958-963.
- Nakayama H., Kuroda H., Fujita J. and Kitamura Y. (1988). Studies of *Sl/Sl^d* in equilibrium with *+/+* mouse aggregation chimeras. I. Different distribution patterns between melanocytes and mast cells in the skin. *Development* 102, 107-116.
- Nakayama H., Kuroda H., Onoue H., Fujita J., Nishimune Y., Matsumoto K., Nagano T., Suzuki F. and Kitamura Y. (1988). Studies of *Sl/Sl^d* in equilibrium with *+/+* mouse aggregation chimeras. II. Effect of the steel locus on spermatogenesis. *Development* 102, 117-126.
- Natali P.G., Nicotra M.R., Sures I., Santoro E., Bigotti A. and Ullrich A. (1992a). Expression of c-kit receptor in normal and transformed human nonlymphoid tissues. *Cancer Res.* 52, 6139-6143.
- Natali P.G., Nicotra M., Winkler A.B., Cavaliere R., Bigotti A. and Ullrich A. (1992b). Progression of human cutaneous melanoma is associated with loss of expression of c-kit protooncogene receptor. *Int. J. Cancer* 52, 197-201.
- Nocka K., Majumder S., Chabot B., Ray P., Cervone M., Bernstein A. and Besmer P. (1989). Expression of c-kit gene products in known cellular targets of W mutations in normal and W mutant mice: evidence for an impaired c-kit kinase in mutant mice. *Genes Dev.* 3, 816-826.
- Sekido Y., Takahashi T., Ueda R., Takahashi M., Suzuki H., Nishida K., Tsukamoto T., Hida T., Shimokata K., Zsebo K.M. and Takahashi T. (1993). Recombinant human stem cell factor mediates chemotaxis of small-cell lung cancer cell lines expressing the c-kit proto-oncogene. *Cancer Res.* 53, 1709-1714.
- Skalli O., Ropraz P., Trzeciak A., Benzouana G., Gillesse D. and Gabbiani G. (1986). A monoclonal antibody against alpha-smooth muscle actin: a new probe for smooth muscle differentiation. *J. Cell Biol.* 103, 2787-2796.
- Strohmeier T., Peter S., Hartmann M., Munemitsu S., Ackermann R., Ullrich A. and Slamon D.J. (1991). Expression of the hst-1 and c-kit protooncogenes in human testicular germ cell tumors. *Cancer Res.* 51, 1811-1816.
- Tsai M., Shih L.-S., Newlands G.F.J., Takeishi T., Langley K.E., Zsebo K.M., Miller H.R., Geissler E.N. and Galli S.J. (1991). The rat c-kit ligand, stem cell factor, induces the development of connective tissue-type and mucosal mast cells in vivo. Analysis by anatomical distribution, histochemistry, and protease phenotype. *J. Exp. Med.* 174, 125-131.
- Tsukada T., Tipples D., Gordon D., Ross R. and Gown A.M. (1987). HHF35, a muscle-actin-specific monoclonal antibody. I. Immunocytochemical and biochemical characterization. *Am. J. Pathol.* 126, 51-60.
- Willis R.E. (1973). Secondary tumors of bone. In: *The spread of tumours in the human body*. 3rd ed. Butterworth & Co. London. pp 229-250.
- Williams D.E., Eisenmann J., Baird A., Rauch C., Van Ness K., March C.J., Park L.S., Martin U., Mochizuki D.Y., Boswell H.S., Burgess G.S., Cosman D. and Lyman S.D. (1990). Identification of a ligand for the c-kit proto-oncogene. *Cell* 63, 167-174.
- Yarden Y., Kuang W.S., Yang-Feng T., Coussens L., Munemitsu S., Dull T.J., Chen E., Schlessinger J., Francke U. and Ullrich A. (1987). Human protooncogene c-kit, a new cell surface receptor tyrosine kinase for an unidentified ligand. *EMBO J.* 6, 3341-3351.
- Zsebo K.M., Williams D.A., Geissler E.N., Broudy V.C., Martin F.H., Atkins H.L., Hsu R.Y., Birkett N.C., Okino K.H., Murdock D.C., Jacobsen F.W., Langley K.E., Smith K.A., Takeishi T., Cattanaach B.M., Galli S.J. and Suggs S.V. (1990). Stem cell factor is encoded at the *Sl* locus of the mouse and is the ligand for the c-kit tyrosine kinase receptor. *Cell* 63, 213-224.

Accepted September 17, 1999